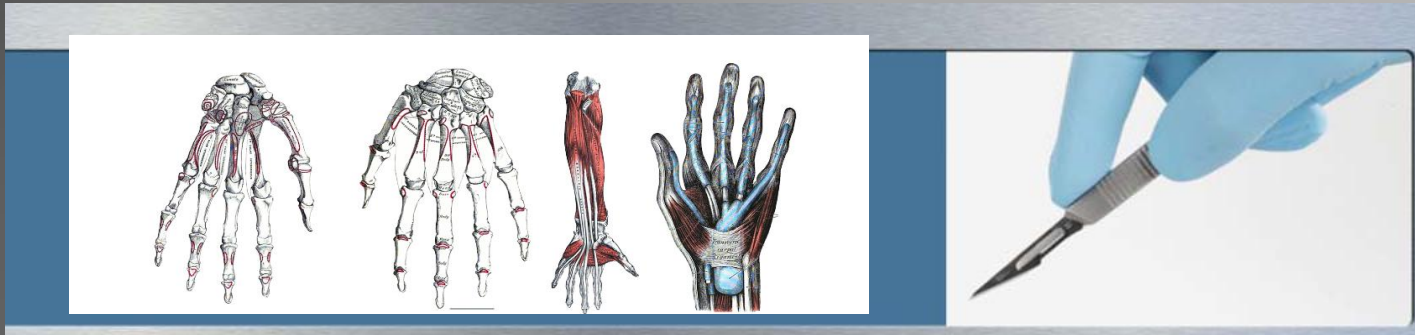


Claudia Senesac, PT, PhD, PCS, is a Clinical Assistant Professor in the Department of Physical Therapy at the University of Florida. She has over 29 years of pediatric clinical experience. She is the owner and administrator of a pediatric physical therapy private practice since 1984 and is a board certified clinical specialist in Pediatrics. Her master's degree is in health science with a focus on motor control. She graduated with a PhD in Rehabilitation Science in 2006 with her research interest focused on motor learning and motor control in the neurologically impaired populations. Dr Senesac has extensive cadaver dissection experience at the University of Florida and teaching Functional Anatomy with emphasis on regional dissection and functional structural relationships in the entry-level Doctorate of Physical Therapy program. She is a consultant in advanced joint dissection in the sports medicine and orthopaedic physical therapy residency programs.





Dedication & Acknowledgements
Introduction

CHAPTER 1 Superficial Back and Posterior Axilla

CHAPTER 2 Pectoral Region

CHAPTER 3 Brachial Plexus

CHAPTER 4 Anterior Surface of the Forearm

CHAPTER 5 Posterior Surface of the Forearm

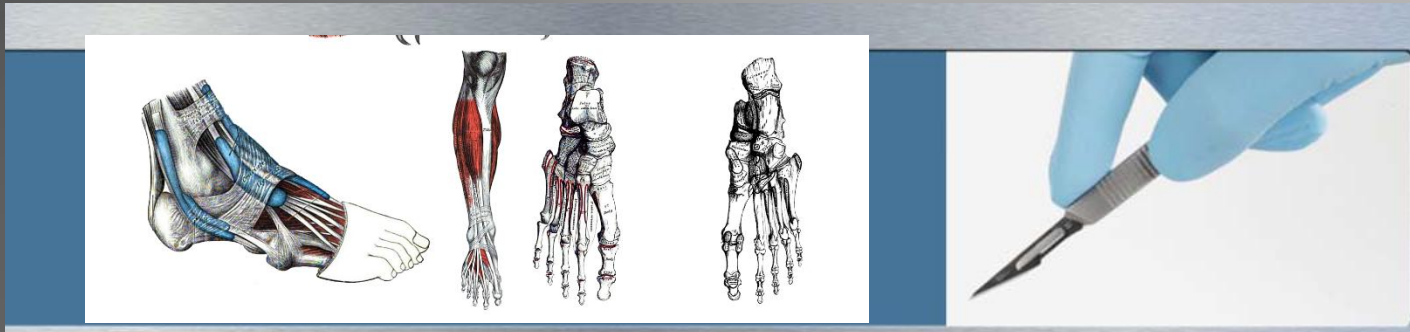
CHAPTER 6 Flexor Surface of the Forearm

CHAPTER 7 Flexor Surface of the Hand

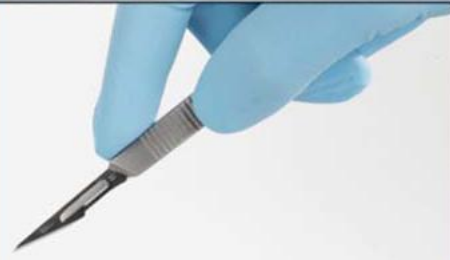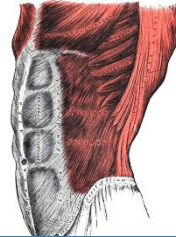
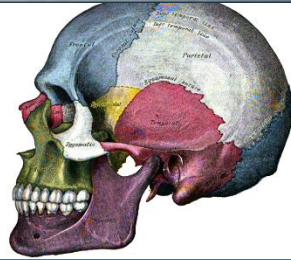
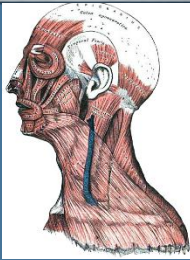
CHAPTER 8 Posterior–Lateral Surface of the Forearm

CHAPTER 9 Dorsum of the Hand

CHAPTER 10 Review of the Upper Limb



- CHAPTER 11 Joints of the Upper Limb
- CHAPTER 12 Anterior Abdominal Wall
- CHAPTER 13 Deep Back and Posterior Neck
- CHAPTER 14 Suboccipital Region
- CHAPTER 15 Laminectomy—The Spinal Cord
- CHAPTER 16 The Lumbar Plexus
- CHAPTER 17 Anterior Thigh—Adductor Thigh
- CHAPTER 18 Posterior Hip
- CHAPTER 19 Posterior Thigh
- CHAPTER 20 Anterior Leg—Lateral Leg
- CHAPTER 21 Dorsum of the Foot
- CHAPTER 22 Posterior Leg and Popliteal Fossa
- CHAPTER 23 The Sole
- CHAPTER 24 Review of the Lower Limb



- CHAPTER 25 Joints of the Lower Limb
- CHAPTER 26 The Cranium
- CHAPTER 27 The Orbit
- CHAPTER 28 The Face
- CHAPTER 29 Temporomandibular Joint
- CHAPTER 30 Lateral Neck
- CHAPTER 31 Anterior Neck
- CHAPTER 32 The Larynx
- CHAPTER 33 Autonomic Nervous System
- CHAPTER 34 The Thorax—The Lungs
- CHAPTER 35 The Thorax—The Heart
- CHAPTER 36 Abdominal Contents
- CHAPTER 37 Pelvis and Perineum—Male
- CHAPTER 38 Pelvis and Perineum—Female